

Can we place tension-free vaginal tape where it should be? The one-third rule

J. KOCISZEWSKI*, O. RAUTENBERG†, A. KUSZKA*, J. EBERHARD†, R. HILGERS‡
and V. VIERECK†§

*Department of Gynecology and Obstetrics, Lutheran Hospital, Hagen-Haspe, Germany; †Department of Gynecology and Obstetrics, Cantonal Hospital, Frauenfeld, Switzerland; ‡Department of Medical Statistics, Georg August University, Goettingen, Germany; §Department of Gynecology and Obstetrics, Georg August University, Goettingen, Germany

KEYWORDS: introital ultrasound; one-third rule; TVT; urethral length; urethral mobility

ABSTRACT

Objectives The tension-free vaginal tape (TVT) insertion technique generally does not take into account individual urethral length. In this study we investigated whether preoperative sonographic measurement of individual urethral length allows for reliable TVT positioning under the midurethra, which is a critical segment for the continence mechanism.

Methods Urethral length was measured by preoperative introital ultrasonography in 102 consecutive female patients with stress urinary incontinence. TVT procedures were performed as recommended by the manufacturer. The suburethral incisions were initiated at one-third of the sonographically measured urethral length. TVT position and tape–urethra distance were followed up 6 months postoperatively.

Results At 6-month examination of the 102 study participants, 93.1% were cured and 6.9% showed improved continence. TVTs were found in the target range of 50–70% of the urethral length in 88.2% of the cohort. Women with the TVT in the 50–70% urethral length range and a 3–5-mm tape–longitudinal smooth muscle distance had a greater likelihood of being cured without complications ($P < 0.001$).

Conclusions Preoperative sonographic measurement of urethral length, combined with the one-third rule, may aid in reliable midurethral TVT positioning. Copyright © 2012 ISUOG. Published by John Wiley & Sons, Ltd.

INTRODUCTION

According to the radiological and morphological examinations of Petros and Ulmsten¹, positioning of tension-free vaginal tape (TVT) ought to be under the middle third

segment of the urethra, also known as the high-pressure zone. This is the zone between the point of maximum urethral closure pressure at rest and the urethral knee (the site of attachment of the pubourethral ligaments), and it is the most critical segment of the urethra for ensuring continence in women^{1,2}. Westby *et al.*³ estimated that this zone lies between 53 and 72% of the functional urethral length. Based on these calculations, we estimated the target range for TVT placement to be between 50 and 70% of the urethral length.

The standard approach of Ulmsten *et al.*⁴ did not take into account individual urethral length when performing the TVT procedure. According to this approach, the distal end of the tape is positioned 10 mm proximal to the external urethral orifice, which is also the site where the suburethral incision begins. Findings from a previous study by our research team, conducted with 72 patients who underwent this traditional TVT approach, showed that tapes were not consistently positioned under the midurethra owing to natural differences in urethral length, which varies between 2 and 5 cm⁵. These results lend support to our claim that midurethral TVT positioning may be more reliably accomplished by first measuring individual urethral length. Ultrasonography is a simple, fast, reproducible and dynamic examination technique and it is a well established urogynecologic diagnostic tool for visualizing the urethra and other lower urinary tract structures in women with stress urinary incontinence^{6–9}.

Based on data obtained from the abovementioned study⁵ and growing interest in the field to better understand the relevance and influence of TVT position on patients' outcomes^{10–12}, we decided to follow up our previous work with the present study aimed at investigating whether preoperative sonographic measurement of individual urethral length allows for reliable TVT positioning under the midurethra.

Correspondence to: Prof. V. Viereck, Department of Gynecology and Obstetrics, Cantonal Hospital Frauenfeld, Postfach, CH-8501 Frauenfeld, Switzerland (e-mail: volker.viereck@stgag.ch)

Accepted: 6 July 2011

METHODS

This study analyzes data collected from 102 consecutive female patients with clinically and urodynamically proven stress urinary incontinence who underwent a TVT procedure in the Department of Urogynecology at Lutheran Hospital Hagen-Haspe, Germany, between January 2007 and August 2009. Since all patients underwent routine examination, the study was determined to be exempt from formal ethics approval by the institutional review board of the University of Goettingen, Germany (reference 14910). The data were collected in accordance with the same standards used in clinical trial settings.

Stress urinary incontinence was verified by a clinical examination and urodynamic testing. The preoperative evaluation also included completion of a fluid intake and voiding diary, a 1-h pad test, and a self-administered incontinence questionnaire that was modified from a questionnaire proposed by Ulmsten *et al.*^{5,13,14}. Patients rated their subjective distress related to incontinence on a visual analog scale (VAS) ranging from 0 to 10, with 0 being 'no incontinence-related distress' and 10 'unbearable distress related to incontinence'.

Preoperative introital ultrasonography was performed in a standardized manner using a Toshiba Aplio ultrasound system (Toshiba, Tokyo, Japan)⁸. With the patient in the semi-sitting position and a standardized bladder-filling volume of 300 mL, the probe (a 3.6–8.3-MHz vaginal transducer with a beam angle of 160°) was placed in the area of the vaginal introitus at the level of the external urethral orifice, exerting minimal pressure and aligning the axis of the probe with the patient's body axis. With this probe in position the urinary bladder, urethra, suburethral vagina and the pubic symphysis with the interpubic disc were visualized in the median sagittal plane and the length of the hypoechoic core of the urethra was measured.

The four urogynecologists involved in the study performed the TVT procedure according to the manufacturer's instructions^{4,5,15}. The standard procedure begins by emptying the bladder through a transurethral Foley catheter. Local anesthetic is injected into the abdominal skin just above the pubic symphysis and downwards along the back of the pubic bone to the space of Retzius. Two 0.5-cm transverse skin incisions 4 cm apart are made close to the superior rim of the pubic bone. Prilocaine–epinephrine solution is injected into the vaginal wall sub- and paraurethraly and a sagittal incision of ≤ 1.5 cm is made in the midline of the suburethral vaginal wall. In order to achieve midurethral tape positioning as recommended by Ulmsten *et al.*¹⁶, the site for beginning the suburethral incision is calculated using the following formula: distance of the distal end of the vaginal incision from the external urethral orifice = one-third of the sonographic urethral length (Figure 1). This initial incision is extended laterally to either side of the urethra by 1.0 cm blunt dissection with scissors. With a catheter guide introduced into the Foley catheter, the urethra and the bladder neck are identified. The tip of the needle is inserted into

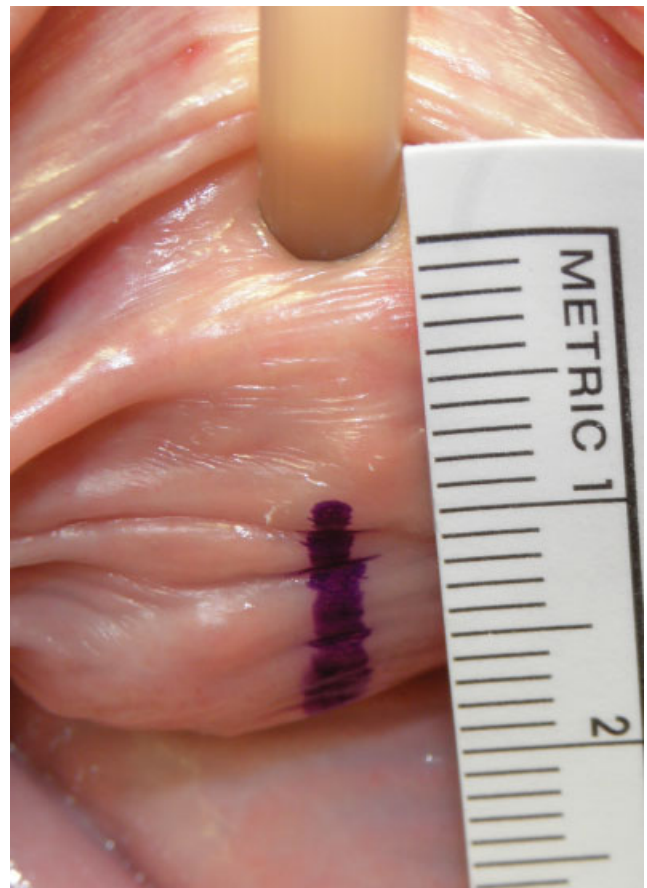


Figure 1 Intraoperative measurement to identify the beginning of the suburethral incision according to the one-third rule when placing tension-free vaginal tape. The 1.5-cm suburethral incision starts at a distance equal to one-third of the sonographically measured length of the urethra from the external urethral orifice.

the prepared paraurethral incision on the right side of the urethra. The urogenital diaphragm is perforated and the tip of the needle brought up to the abdominal incision in close contact with the back of the pubic bone. As soon as the needle tip reaches the abdominal skin incision, the proximal end of the needle is disconnected from the handle and the tape (covered by the plastic sheath), and is brought into position on this side of the urethra by pulling the needle upward with the tape attached. The procedure is then repeated on the left side. At this point a cystoscopy is performed to confirm an intact bladder. With 300 mL of saline in the bladder, the patient is asked to cough vigorously to confirm that continence has been achieved. When necessary, final adjustment and repositioning of the tape are performed. Once the tape has been positioned in the recommended U-shape around the midurethra, the plastic sheath is withdrawn. The vaginal incision is then closed and the bladder emptied.

Postoperative evaluation of incontinence conducted during hospitalization for the TVT insertion (1–5 days) and at 6-month follow-up visits included patients' reports, clinical findings, pad-test results and introital ultrasound^{5,14}. The postoperative ultrasound examination was performed with a sonographically verified bladder filling of 200–300 mL. Sonographically, in median sagittal

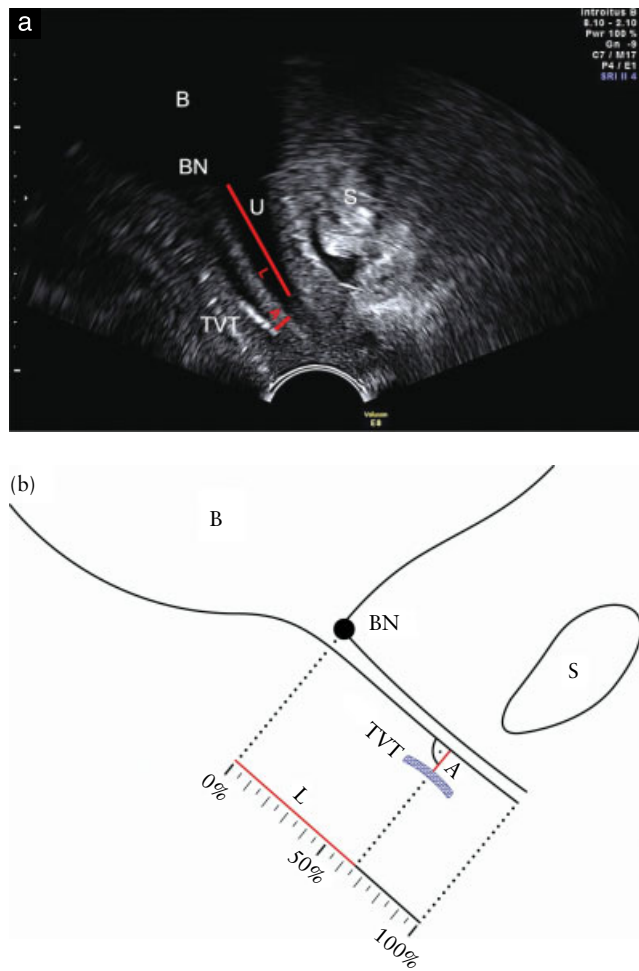


Figure 2 Determination of distance of tension-free vaginal tape (TVT) from echolucent part of the urethra (U) consisting of mucosa, submucosa and smooth muscle layers (longitudinal smooth muscle (LSM) complex) i.e. the tape–LSM distance (A). (a) Introital ultrasound image; (b) schematic representation. The interface between the layers and the echogenic striated urogenital sphincter muscle is visualized consistently on ultrasound (short red line in (a)). B, bladder; BN, bladder neck; L, percentage of urethral length relative to mid-tape; S, symphysis pubis.

orientation, the position of the TVT (mid-tape) along the urethra was determined and expressed as percentage of urethral length. To better characterize the location of the TVT, the shortest distance between the tape and the longitudinal smooth muscle (LSM) complex of the urethra, also called the tape–LSM distance, was measured. This was done by drawing a perpendicular line from the urethral lumen to the tape (Figure 2). In addition, the residual postvoid bladder volume was sonographically determined to rule out voiding dysfunction. Voiding dysfunction was defined as ‘abnormally slow and/or incomplete micturition’¹⁷ and a postmicturition residual volume of more than 100 mL. In patients with voiding dysfunction, introital ultrasound was performed on the first postoperative hospitalization day. If the tape–LSM distance was less than 3 mm, the tape was mobilized. Tape mobilization was performed as follows: (1) reopening the suburethral incision in the vagina, (2) locating the tape and (3) carefully pulling down on the tape laterally with a

clamp to the desired distance indicated by ultrasound, taking care not to disturb the suburethral integrity of the tape.

Consistent with the recommendations of Ulmsten *et al.*¹³ published in 1999, the success of the TVT procedure was assessed using a combination of objective and subjective criteria⁵. Patients with a negative cough test, a negative 1-h pad test (< 2 g difference) and a VAS score of 0 or 1 at the time of the postoperative evaluation were classified as being cured. Criteria for classifying a patient as improved were the involuntary loss of only a few drops during straining or a 1-h pad test with a difference of 2–10 g (or a reduction of > 50%) and a VAS score of 2 or 3. All other patients were classified as treatment failures, even if one aspect showed marked improvement from the preoperative condition.

Statistical analysis was performed using Fisher’s exact test, and results were considered significant at $P < 0.05$.

RESULTS

The median age of the 102 study participants was 61.5 (range, 35–80) years, and the group had a mean body mass index of 26.8 (range, 19–40) kg/m². The median number of previous vaginal deliveries was 2 (range, 0–6). Nine patients had a history of Cesarean section.

At the 6-month follow-up visit, 95 of the 102 women (93.1%) were cured and seven (6.9%) had improved. The distal end of the incision, calculated according to the formula presented above, was at a distance ranging from 8 to 13 mm (median, 10 mm) from the external urethral orifice. Taking into account individual urethral length in planning the suburethral incision, tape positioning between < 70 and > 50% of the percentage urethral length was accomplished in 90 (88.2%) patients. In two of the seven patients who improved but were not cured at the 6-month follow-up visit, the tape was located at > 70% of the urethral length. Analysis of the tape–LSM distance showed that three of the 12 patients with tape positioned > 5 mm from the urethral lumen had only an improved outcome. With regard to complications, a total of seven patients experienced complications at the 6-month follow-up visit (six patients had urgency and one had voiding difficulty). In six of these patients the tape was located less than 3 mm from the LSM.

The results indicate that patients with the tape positioned at < 70 and > 50% and at a distance of 3–5 mm from the LSM complex of the urethra were more likely to be cured without complications than those with the tape positioned outside this range ($P < 0.001$). Furthermore, TVTs placed too far from the LSM (> 5 mm) were associated with a 10-fold higher risk of not being cured (Figure 3) ($P = 0.026$).

On the first postoperative day, voiding dysfunction was seen in nine (8.8%) patients, all of whom had a tape–LSM distance of < 3 mm. Eight of the nine patients who required tape mobilization were cured without complications at the 6-month follow-up visit. In the patient with persistent voiding dysfunction, the tape–LSM distance continued to be < 3 mm despite the

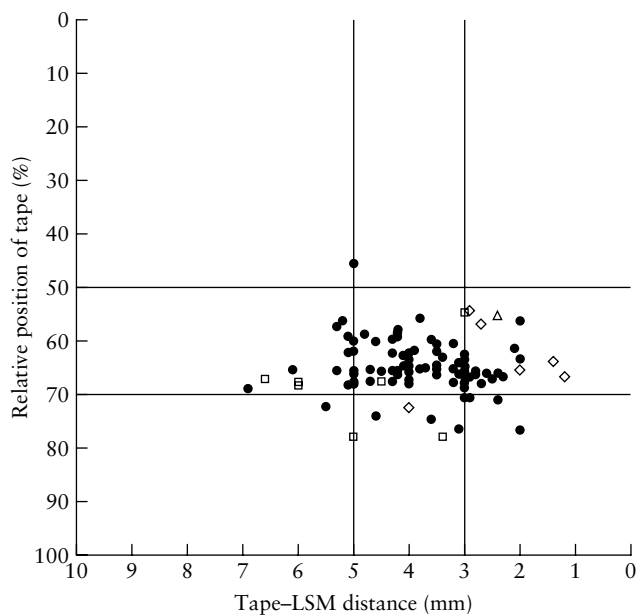


Figure 3 Outcome and complications, at 6-month follow-up, according to tape-LSM (longitudinal smooth muscle complex of the urethra) distance and position of the mid-point of the tape relative to the length of the urethra. The tape position was at >50% and <70% of the urethral length in 88.2% of patients (90/102); patients with this tape position and a tape-LSM distance of 3–5 mm are more likely to be cured without complications at 6-month follow-up ($P < 0.001$). ●, cured, no complications; ◇, cured, urgency; △, cured, voiding difficulty; □, improved.

attempt to mobilize the tape. Seven of the nine patients with tape mobilization had a hypomobile urethra (defined as linear dorsocaudal movement of < 5 mm) with vertical descent^{18,19}, which was detected in a total of 40 study participants.

DISCUSSION

Ultrasonography is a versatile, non-invasive diagnostic tool widely available in standard clinical settings. The technique of urogynecological ultrasound, which is used to evaluate the lower urinary tract and the position of the TVT at rest and during straining in patients treated for urinary incontinence, is easy to learn and provides detailed information on the anatomy and function of the lower urinary tract^{5,8,12,18,19}.

In our previous sonographic observational study of 72 women with clinically and urodynamically proven stress urinary incontinence who underwent TVT placement using the standard approach for starting the incision, a wide variation in tape position relative to the percentage urethral length of each patient was observed⁵. Additionally, the results showed significantly better outcomes when the TVT was under the middle third of the urethra. These results support the theoretical assumption that reliable TVT position is not achieved consistently unless individual urethral length is taken into consideration.

Interestingly, the recommended site for suburethral incision has been modified over time. While in earlier publications Ulmsten *et al.* suggested an incision 'starting

approximately 0.5 cm from the outer urethral meatus', in later publications they recommend a slightly more proximal incision 'starting 1 cm from the outer urethral meatus'^{13,16,20}. This approach was adopted by Ethicon (Johnson & Johnson) and is currently recommended as the standard procedure. However, a review of the literature on incontinence surgery reveals additional discrepancies, as experienced surgeons suggest an even more proximal site with 'a small incision 1.5 cm from the outer urethral meatus'²¹.

Although the surgical procedures included in this study were done by four different surgeons, it was possible to achieve midurethral tape position in the majority (88.2%) of patients. Positioning of the TVT along the midurethra (under the urethral segment most critical for the continence mechanism) was identified by determining the beginning of the incision on the basis of the sonographically measured urethral length. This was done using the one-third rule presented above. The favorable outcomes seen in patients with TVTs positioned between 50 and 70% of their total urethral length warrant further investigation with a more rigorous research design, such as a randomized controlled trial.

These results are consistent with the findings of earlier studies^{5,14}, as well as the pathophysiological assumptions of Petros and Ulmsten¹. Recently published work from two other research groups^{11,12} indicates that midurethral placement of the tape relative to the urethra has an impact on the outcome. Nevertheless, the role of TVT placement discussed in the scientific literature is not without controversy. Dietz *et al.*^{22,23} did not find significant effects of midurethral tape placement on postoperative outcomes; however, these findings are not directly comparable since the pubic symphysis was used as the point of reference, not the urethra. Furthermore, Duckett *et al.*¹² found that distal placement of the tape may cause less alteration in flow rates than midurethral placement.

Despite our efforts to position the TVT in the target area with the aid of ultrasound, the tape came to lie under the distal urethra in a few patients and in one case the tape was too proximal. Unintentional TVT placement under the distal urethra may have been the result of too much pressure applied by the ultrasound probe. Consequently, the suburethral incision was done too far distally, which led to TVT positioning outside the midurethral range. Two cases had only an improved outcome despite having the TVT positioned along the midurethra and within a tape-LSM distance of 3–5 mm. However, postoperative ultrasound examination in the coronal plane revealed tape asymmetry, which most probably precluded desirable tape function and full restoration of continence.

Postoperative ultrasound allows for identification of the causes of obstructive complications. Immediate mobilization of the tape on the first or second postoperative day successfully restored normal bladder voiding in eight of the nine patients with voiding dysfunction and failed in only one of them. In this one case, ultrasound showed an unchanged TVT position. The benefits of early tape mobilization were also confirmed in a recent study by

Price *et al.*²⁴. The tape mobilization procedure constitutes an early intervention conducted during initial hospitalization, which is designed to prevent long-term and potentially more severe postoperative complications. Tape mobilization involves a variation from the traditional approach of Ulmsten *et al.*; therefore, the incidence of postoperative complications in this study may be confounded by this intervention.

Although the one-third rule is promising with respect to improving the reliability of TVT placement along the urethra, it cannot control the tape–LSM distance. Nevertheless, measurement of this parameter could be of value in the management of early postoperative complications.

Our results suggest that complications associated with individually planned TVT placement are probably attributable to (1) proximity of the tape to the LSM rather than tape position along the urethra and (2) hypomobility of the urethra. Almost all cases of *de novo* urgency and voiding dysfunction were observed in patients with a tape–LSM distance of < 3 mm. Likewise, disturbed voiding was more common in patients with an immobile urethra and vertical descent. In these cases, it is far more difficult to achieve a desirable tape–LSM distance than in patients with a hypermobile bladder neck. The range of suitable tension levels is much narrower in patients with vertical descent than in those with mixed descent. Therefore, correct tape–LSM distance appears to be critical in achieving a high cure rate in patients with vertical descent. Moreover, the risk of overcorrection is higher in these patients.

Preoperative sonographic measurement of the urethral length, combined with the one-third rule, aids in reliable placement of the TVT under the distal end of the mid-third of the urethra. While the one-third rule does not prevent complications resulting from hypomobility or the TVT's being placed too near the LSM, tape positioning in the target range along the urethra can be achieved in the majority of cases using this approach.

REFERENCES

- Petros PE, Ulmsten UI. An integral theory of female urinary incontinence. Experimental and clinical considerations. *Acta Obstet Gynecol Scand* 1990; 153 (Suppl.): 7–31.
- Dietz HP, Wilson PD. Anatomical assessment of the bladder outlet and proximal urethra using ultrasound and videocystourethrography. *Int Urogynecol J Pelvic Floor Dysfunct* 1998; 9: 365–369.
- Westby M, Asmussen M, Ulmsten U. Location of maximum intraurethral pressure related to urogenital diaphragm in the female subject as studied by simultaneous urethrocystometry and voiding urethrocystography. *Am J Obstet Gynecol* 1982; 144: 408–412.
- Ulmsten U, Henriksson L, Johnson P, Varhos G. An ambulatory surgical procedure under local anesthesia for treatment of female urinary incontinence. *Int Urogynecol J Pelvic Floor Dysfunct* 1996; 7: 81–85.
- Kociszewski J, Rautenberg O, Perucchini D, Eberhard J, Geissbühler V, Hilgers R, Viereck V. Tape functionality: sonographic tape characteristics and outcome after TVT incontinence surgery. *Neurourol Urodyn* 2008; 27: 485–490.
- Harms L, Emons G, Bader W, Lange R, Hilgers R, Viereck V. Funneling before and after anti-incontinence surgery – a prognostic indicator? Part 2: tension-free vaginal tape. *Int Urogynecol J Pelvic Floor Dysfunct* 2007; 18: 289–294.
- Masata J, Martan A, Svabik K, Drahoradova P, Pavlikova M. Ultrasound imaging of the lower urinary tract after successful tension-free vaginal tape (TVT) procedure. *Ultrasound Obstet Gynecol* 2006; 28: 221–228.
- Tunn R, Schaer G, Peschers U, Bader W, Gauruder A, Hanzal E, Koebel H, Koelle D, Perucchini D, Petri E, Riss P, Schuessler, Viereck V. Updated recommendations on ultrasonography in urogynecology. *Int Urogynecol J Pelvic Floor Dysfunct* 2005; 16: 236–241.
- Viereck V, Bader W, Krauss T, Oppermann M, Gauruder-Burmester A, Hilgers R, Hackenberg R, Hatzmann W, Emons G. Intra-operative introital ultrasound in Burch colposuspension reduces post-operative complications. *BJOG* 2005; 112: 791–796.
- Smith AR, Koelbl R. Is mid-urethral placement of synthetic minimal access tapes important in stress urinary incontinence surgery? *Neurourol Urodyn* 2010; 29: 676–678.
- Flock F, Kohorst F, Kreienberg R, Reich A. Ultrasound assessment of tension-free vaginal tape (TVT). *Ultraschall Med* 2011; 32 (Suppl.): S35–S40.
- Duckett J, Basu M, Papanikolaou N. Transperineal ultrasound to assess the effect of tension-free vaginal tape position on flow rates. *Ultrasound Obstet Gynecol* 2010; 36: 379–383.
- Ulmsten U, Johnson P, Rezapour M. A three-year follow up of tension free vaginal tape for surgical treatment of female stress urinary incontinence. *Br J Obstet Gynaecol* 1999; 106: 345–350.
- Kociszewski J, Rautenberg O, Kolben S, Eberhard J, Hilgers R, Viereck V. Tape functionality: position, change in shape and outcome after TVT procedure – mid-term results. *Int Urogynecol J Pelvic Floor Dysfunct* 2010; 21: 795–800.
- Ulmsten U. An introduction to tension-free vaginal tape (TVT) – a new surgical procedure for treatment of female urinary incontinence. *Int Urogynecol J Pelvic Floor Dysfunct* 2001; 12 (Suppl.): S3–S4.
- Ulmsten U, Petros P. Intravaginal slingplasty (IVS): an ambulatory surgical procedure for treatment of female urinary incontinence. *Scand J Urol Nephrol* 1995; 29: 75–82.
- Haylen BT, de Ridder D, Freeman RM, Swift SE, Berghmans B, Lee J, Monga A, Petri E, Rizk DE, Sand PK, Schaer GN; International Urogynecological Association; International Continence Society. An International Urogynecological Association (IUGA)/International Continence Society (ICS) joint report on the terminology for female pelvic floor dysfunction. *Neurourol Urodyn* 2010; 29: 4–20.
- Viereck V, Pauer HU, Hesse O, Bader W, Tunn R, Lange R, Hilgers R, Emons G. Urethral hypermobility after anti-incontinence surgery – a prognostic indicator? *Int Urogynecol J Pelvic Floor Dysfunct* 2006; 17: 586–592.
- Viereck V, Nebel M, Bader W, Harms L, Lange R, Hilgers R, Emons G. Role of bladder neck mobility and urethral closure pressure in predicting outcome of tension-free vaginal tape (TVT) procedure. *Ultrasound Obstet Gynecol* 2006; 28: 214–220.
- Ulmsten U. TVT – Tension-free vaginal tape: An ambulatory surgical procedure under local anesthesia for treatment of female stress urinary incontinence. *Riv It Biol Med* 1997; 17: 40–43.
- Ralph G, Riss P. Die operative Behandlung der Stressinkontinenz – Vaginal oder abdominal. *Der Gynäkologe* 2002; 26: 489–498.
- Dietz HP, Mouritsen L, Ellis G, Wilson PD. How important is TVT location? *Acta Obstet Gynecol Scand* 2004; 83: 904–908.
- Chantarasorn V, Shek K, Dietz H. Predictors of failure after Monarc suburethral sling. *Int Urogynecol J Pelvic Floor Dysfunct* 2009; 20: S332–S333.
- Price N, Slack A, Khong SY, Currie I, Jackson S. The benefit of early mobilisation of tension-free vaginal tape in the treatment of post-operative voiding dysfunction. *Int Urogynecol J Pelvic Floor Dysfunct* 2009; 20: 855–858.