

See discussions, stats, and author profiles for this publication at: <https://www.researchgate.net/publication/244482335>

Ultrasound and Early Tape Mobilization—A Practical Solution for Treating Postoperative Voiding Dysfunction

Article in *Neurourology and Urodynamics* · September 2014

DOI: 10.1002/nau.22459 · Source: PubMed

CITATIONS

22

READS

100

6 authors, including:



[Jacek Kociszewski](#)

Lutheran Hospital, Hagen, Germany

39 PUBLICATIONS 297 CITATIONS

[SEE PROFILE](#)



[Volker Viereck](#)

Kantonsspital Frauenfeld

124 PUBLICATIONS 2,460 CITATIONS

[SEE PROFILE](#)

Ultrasound and Early Tape Mobilization—A Practical Solution for Treating Postoperative Voiding Dysfunction

Oliver Rautenberg,¹ Jacek Kociszewski,² JoEllen Welter,^{1,2} Andrzej Kuszka,² Jakob Eberhard,¹ and Volker Viereck^{1,3*}

¹Department of Gynecology and Obstetrics, Cantonal Hospital Frauenfeld, Frauenfeld, Switzerland

²Department of Gynecology and Obstetrics, Lutheran Hospital Hagen-Haspe, Hagen, Germany

³Department of Gynecology and Obstetrics, Georg August University Goettingen, Goettingen, Germany

Aims: This study assessed the effectiveness of ultrasound in determining tape distance to urethra and the impact of early tape mobilization on outcomes in women with postoperative voiding dysfunction resulting from a too tightly positioned tension-free vaginal tape (TVT). **Methods:** A prospective observational study was conducted with women experiencing voiding dysfunction caused by too tightly positioned tapes. Ultrasound was used to identify the cause of the dysfunction and measure the distance between tape and longitudinal smooth muscle layer (LSM) of the urethra. If the tape was too close to the LSM (<3 mm) and the residual volume was >100 ml, it was mobilized under local/analgesedation shortly after the initial TVT procedure. **Results:** Seventy-one postoperative TVT mobilization procedures were conducted on 61 women, which was 4.1% (61/1501) of all suburethral tape procedures performed. Early tape mobilization restored normal micturition in 59 (96.7%) of the women at the time of discharge. Significant differences were found in residual volumes ($P < 0.001$) and tape-LSM distances ($P < 0.001$) pre- and post-mobilization. At 6-month follow-up visits, 58 (95.1%) women were cured of SUI, three were incontinent, and no additional voiding dysfunction occurred. **Conclusions:** Immediate postoperative ultrasound can reliably detect too tightly positioned tapes that can be promptly treated with tape mobilization, a short and safe procedure that does not compromise the outcome of the original procedure. *Neurourol. Urodynam.* 33:1147–1151, 2014. © 2013 Wiley Periodicals, Inc.

Key words: obstructive voiding dysfunction; pelvic floor ultrasound; stress urinary incontinence; surgical complications; tape mobilization; urinary retention

INTRODUCTION

One inherent complication associated with TVT placement is urethral obstruction with disturbed voiding. With a rate of approximately 1.6–26%, voiding dysfunction is the most commonly experienced postoperative complication.¹ Development of this type of complication is due, in part, to the challenge faced by the operating physician to achieve continence through an adequately supportive tape without causing urinary retention by inserting the tape too tightly.²

Even though voiding dysfunction is one of the most commonly experienced postoperative complications, best practices for managing these cases still remain unclear.³ Options such as conservative treatment or conducting an additional operation both involve risks. The potential to develop further complications from alternatives such as long-term catheterization and its associated increased susceptibility to infection must be considered.¹ According to Chang et al.² the use of prolonged catheterization ranges from 0.6% to 23% and may result in urinary infections, anxiety, and decreased quality of life. Nonetheless, catheterization may be the most suitable alternative if voiding dysfunction is primarily due to postoperative edema since the symptoms will likely improve as the edema subsides. The remaining treatment alternatives are limited to intermittent self-catheterization or tape division (sling incision).¹ However, dividing the tape can result in recurrence of stress incontinence in up to 50% of patients,^{3–6} in addition to incurring additional costs and potentially worsening the patient's quality of life.

Tape mobilization, also referred to as tape loosening, is one effective approach to addressing complications from a tape with too much tension. The primary objective of this procedure is to adjust the tape to a more desirable tension level.^{1,2,7,8}

Widely available technology such as ultrasonography is also being used in the management of postoperative tape complications.⁹ It can be used to assess relevant patient characteristics such as the urethral length and mobility, the height of the vaginal sulcus, and tape positioning. Recently conducted studies by Reich et al.¹⁰ and Yang et al.¹¹ on 4D ultrasound demonstrated good to very good reproducibility concerning TVT position relative to the urethral length and distance to the hypoechoic center of the urethra.

Based on findings from our previous research in which we found an association between a tape distance of <3 mm and postoperative complications, we began to routinely conduct tape mobilizations on patients who would likely benefit from such a procedure.¹² Preliminary results from retrospective record reviews indicated positive patient outcomes and resolution of complications when the mobilization was done within 14 days postoperatively; however, no additional benefits were seen when the procedure was delayed >3 days postoperatively. Although edema can influence postoperative voiding dysfunction, it is experienced, to a certain degree, by all women having a TVT insertion procedure. In both these above-mentioned investigations, voiding dysfunction resolved

Eric Rovner led the peer-review process as the Associate Editor responsible for the paper.

Conflict of interest: none.

*Correspondence to: Prof. Volker Viereck, M.D., Department of Gynecology and Obstetrics, Cantonal Hospital Frauenfeld, Postfach CH-8501, Frauenfeld, Switzerland.

E-mail: volker.viereck@stgag.ch

Received 9 March 2013; Accepted 7 June 2013

Published online 2 July 2013 in Wiley Online Library

(wileyonlinelibrary.com).

DOI 10.1002/nau.22459

simultaneously with edema in those patients with the tape distance >3 mm. In patients with the tape-LSM <3 mm, voiding dysfunction persisted.

The aim of this current study was to describe a model for treating patients with postoperative voiding dysfunction resulting from a too tightly positioned (too narrowly placed) tension-free vaginal tape (TVT). In order to validate this model, we assessed a controlled technique of early tape mobilization to effectively treat these cases.

MATERIALS AND METHODS

To assess the effectiveness of early tape mobilization, all female patients with SUI who had TVT insertion (Gynecare TVT), subsequently experienced voiding dysfunction (defined in accordance with the International Continence Society as slow stream and/or staccato micturition plus a continual postmicturition residual volume of >100 ml¹³), and had a sonographically-measured tape-LSM distance of <3 mm were selected to undergo tape mobilization. The primary outcome of the study was to assess voiding dysfunction, and the secondary outcome was stress urinary incontinence. All tape insertion and mobilization procedures, as well as the 6-month follow-up visits, were conducted at two tertiary urogynecological centers between August, 2008 and July, 2012. Data such as patient characteristics, pre- and post-operative assessments, complications and SUI outcomes were collected and analyzed. Women who needed more than one tape mobilization procedure were also included in the study. None of the study patients had concomitant surgeries.

Both centers provided standardized care prior to TVT insertion that included a detailed medical history, physical examination, pelvic organ prolapse quantification, and multi-channel urodynamic studies. Excluded from the study were any patients who had voiding dysfunction prior to TVT insertion. In all women who underwent prior tape insertion, the tapes were partially removed during a previous operation. Urogynecologists performed the TVT procedures according to the manufacturer's instructions.¹⁴ TVT procedures were performed under local/analgosedation and cough stress tests were used to guide adjustments to the tape tension. A single injection of the antibiotic ceftriaxone (2 g) was given to each patient at the start of the operation. At the conclusion of the procedure, the bladder was emptied.

In accordance with standard postoperative procedures, first voiding was attempted after 2 h. If sonographically-measured residual volumes (BladderScan® BVI 6100) were >200 ml, catheterization was done. Ultrasound was performed on all patients after spontaneous voiding on postoperative days 1–2 (see detailed description of procedure below). Patients with persistently high residual urine volumes (>100 ml) were primarily treated conservatively with anti-inflammatory medication, cholinergic agents and analgesics until the residual volume was <100 ml. Other likely causes of voiding dysfunction—hematoma or edema—were ruled out by ultrasound and were treated conservatively.

Tape mobilization was performed in women with voiding dysfunction whose tape was too tightly placed and were, therefore, at higher risk of experiencing long-term complications. Too tightly placed tapes were defined as having a tape-LSM distance of <3 mm. Findings from our previous research indicated that patients experiencing postoperative voiding dysfunction with a tape-LSM distance ≥ 3 mm generally responded favorably to conservative treatment.¹⁵

In order to most effectively resolve voiding dysfunction when tape mobilization was indicated, the procedure was

carried out during the same hospitalization stay for the original TVT insertion. This was usually performed within 1–3 days postoperatively. Tape mobilization was done in the operating room under local/analgosedation and a single injection of antibiotics (ceftriaxone 2 g) was administered. The procedure continued as follows: (1) reopen the sub-urethral incision in the vagina,² locate the tape, and³ with one laterally placed clamp gently pull down the tape to the desired location while using a second clamp to help control the extent of the downward movement of the first clamp (Fig. 1). In cases of asymmetrically placed tape, the side of the tape closest to the urethra was loosened. If the initial attempt at mobilization was ineffective (persistent residual volumes above 100 ml plus no change in tape-LSM distance as determined by ultrasound), a second attempt was made shortly after the first and during this same hospitalization.

The postoperative care was consistent with the care following a TVT insertion described above. Most patients with normal micturition were discharged from the hospital the same day or the day after the tape mobilization procedure when no additional complications were experienced. Patient assessments conducted at 2 weeks (± 1 week) for micturition control and follow-up at 6 months (± 1 month) after the original TVT insertion procedure included a complete medical history and urogynecologic examination. At 6-month follow-up visits, patients' outcomes following TVT insertion and tape mobilization were evaluated using a combination of objective and subjective criteria. Patients were classified as cured if the postoperative cough test was negative, the 1-h pad test was negative (<2 g difference), and the degree of subjective suffering improved (VAS score of 0 or 1). All other patients were classified as treatment failures, even though one indicator may have improved from the patient's preoperative condition.^{12,15}

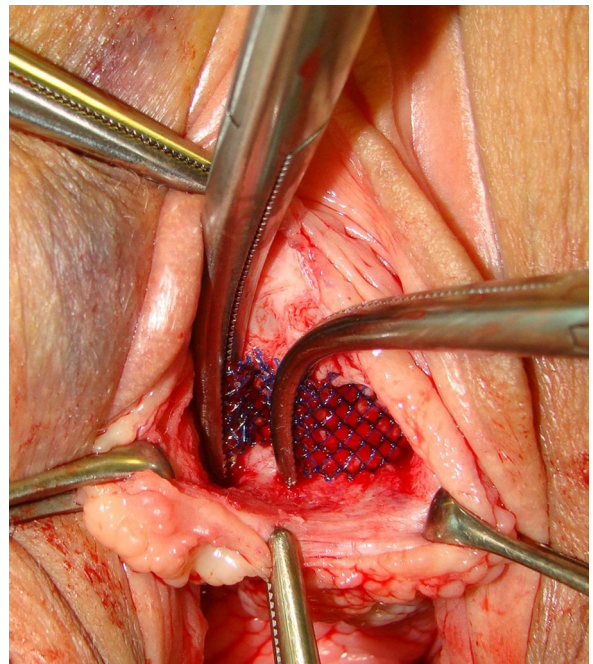


Fig. 1. Intraoperative image demonstrating the position of the clamps used in a controlled tape mobilization procedure. The tape is gently pulled down with the laterally placed clamp to the desired location while using a second clamp to control the extent of the downward movement of the first clamp.

Measurements of the tape-LSM were conducted as follows: ultrasound was performed on all patients after spontaneous voiding on postoperative days 1–3 (GE Voluson 730, GE Healthcare, Chalfont St. Giles, United Kingdom). A transvaginal probe (5–9-MHz, beam angle of 160°) was used in the sagittal and axial view to determine tape position or tightness, and to detect asymmetrically placed tape. In order to determine the proximity of the tape to the urethra, the shortest distance between the tape and the longitudinal smooth muscle (LSM) complex of the urethra, also called the tape-LSM distance, was measured at rest.^{4,12,15} This was done by drawing a perpendicular line from the LSM to the tape (Fig. 2). The shortest distance (suburethral or lateral) between the tape and the LSM, measured in mm, serves as an indication of the tension level of the tape since compression on the surrounding tissue seems to be associated with the proximity of the tape to the LSM. Urethral length was measured on a median sagittal scan with 300-ml bladder filling from the bladder neck to the distal end of the hypoechoic urethra (ending at the hyperechoic urethral papilla). The position of the tape along the urethra (mid-sling as reference point) was determined and expressed as percentage of entire urethral length.

SPSS (version 19.0.0) was used to conduct the data analysis for this study. Wilcoxon signed ranks tests using a significance level of 0.05 were done to compare means prior to and following surgical interventions. The study protocol was reviewed and accepted by the ethics commission (reference numbers EKKt.TGA3/0608 and EK8/6/08).

RESULTS

A total of 1,501 TVT insertions were performed during this 4-year period. Seventy-one tape mobilization procedures were

done on 61 patients who experienced voiding dysfunction following tape insertion, which represents 4.1% of all TVT placement procedures for both centers. Table I presents key characteristics of the women included in this study. Post-void residual urine measurements conducted prior to tape insertion were between 0 and 65 ml (mean 11.4 ± 13.8); indicating that none of the patients had preoperative clinical voiding dysfunction. Preoperative maximal urethral closure pressure in standing position ranged from 14 to 93 cmH₂O (mean 37.3 ± 15.8). The maximal flow rate on voiding cystometry (Qmax) ranged from 13.5 to 62.0 ml/sec (mean 30.6 ± 11.9). Nine (14.8%) patients had a reduced Qmax < 20 ml/sec. Eighteen (29.5%) patients who underwent tape mobilization had a hypomobile urethra (defined as linear dorsocaudal movement [LDM] < 5 mm with vertical descent).^{16,17}

Early tape mobilization was performed at a median of 2.0 days (range 1–4) after the original procedure. Second tape mobilization attempts were done on 10 of the 61 patients at a median of 6.0 days (range 2–9) after tape placement and within the same hospitalization stay. The median duration of the tape mobilization procedures was 10.0 min (range 5–21). The suspected cause of the obstruction—the tape’s proximity to the LSM—was confirmed during the procedure. Wilcoxon signed ranks tests showed statistically significant differences in the residual volume (*P* < 0.001) and the tape-LSM distance (*P* < 0.001) pre- and post-tape mobilization procedures. The median residual volume prior to TVT mobilization was 260 ml (range 100–640) and 40 ml (range 0–430) on the first postoperative day after the last tape mobilization attempt. The median tape-LSM distance measured before and after the last TVT mobilization was 1.9 mm (range 0–2.9) and 3.4 mm (range 2.0–6.5), respectively (Fig. 3). No perforations of the urethra were observed. The postoperative complications following all tape mobilization procedures were two minor hematomas which were treated conservatively. No additional complications, including infections, were experienced.

Tape mobilization successfully restored normal bladder voiding immediately after the first attempt at mobilization in 51 (83.6%) of the 61 women and in a total of 59 (96.7%) patients following the second attempt made during the same hospitalization stay. Of the 10 patients who required a second mobilization, nine eventually had normal voiding function. Seven of these 10 patients had a hypomobile urethra (defined as linear dorsocaudal movement [LDM] < 5 mm) with vertical descent,^{16,17} which was detected in a total of 18 (29.5%) of the study participants.

One patient with unresolved voiding function opted for tape incision following the TVT mobilization procedure. SUI recurred

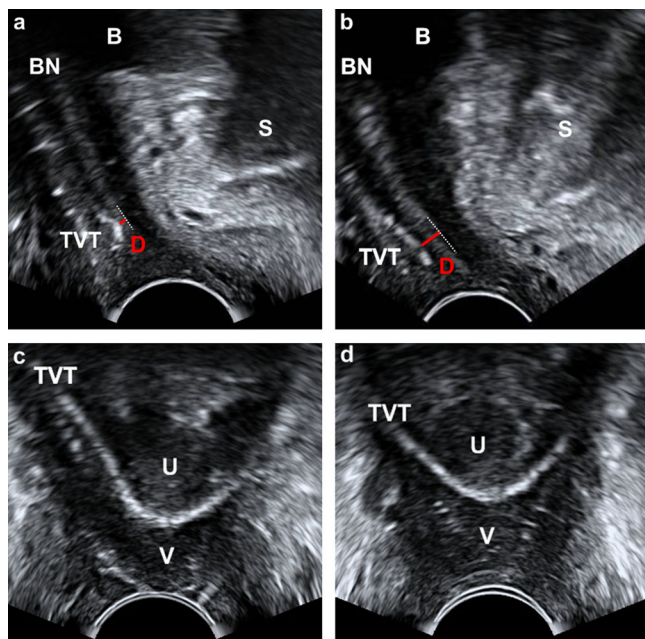


Fig. 2. Pelvic floor ultrasound images illustrating the tape-LSM distance and tape symmetry before and after tape mobilization. Panels (a), sagittal view, and (c), axial view, illustrate tape-LSM distance and asymmetry before and panels (b), sagittal view, and (d), axial view, after tape mobilization (B, bladder; BN, bladder neck, S, symphysis pubis, D, shortest distance between the tape and the longitudinal smooth muscle (LSM) complex of the urethra, U, urethra, V, vagina).

TABLE I. Patient Characteristics (n = 61)

Age (years)	61 ± 13	(35–85)
BMI (kg/m ²)	26 ± 4	(20–38)
Vaginal parity	2 ± 1	(0–6)
Delivery history		
Spontaneous	44	(72%)
Caesarean	7	(11%)
No parturition	6	(10%)
Vacuum extractions	3	(5%)
Previous incontinence surgery	11	(18%)
TVT-S	1	
TVT	5	
TVT-O	2	
Burch	3	

Data presented as mean ± SD (range) or n (%).

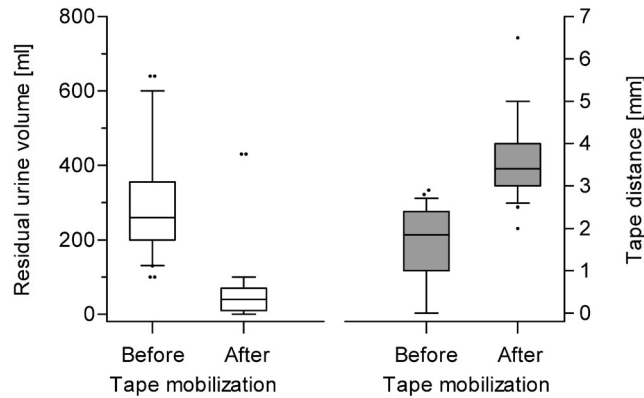


Fig. 3. Residual urine volume and tape-LSM distance for patients before and after they undergo a tape mobilization procedure.

after tape incision, and eventually this patient had a second tape insertion procedure. One case with unresolved voiding function had transient self-catheterization for a few weeks until normalization of residual volume. Follow-up visit assessments revealed that the patient was still experiencing SUI. With regard to long-term success rates of the original tape placement procedure, 58 (95.1%) patients were cured of stress urinary incontinence and normal residual volume (<100 ml) was restored in 59 (96.7%) of the women at 6-month follow-up visits.

DISCUSSION

This prospective study assesses the effectiveness of measuring tape positioning using ultrasound imaging and early tape mobilization to treat postoperative voiding dysfunction, the most common complication following TVT surgery.¹ Findings from this study indicate that this treatment method of using pelvic floor ultrasound to detect too tightly placed TVTs causing postoperative obstructive voiding dysfunction and then conducting early “site dependent” tape mobilization can restore normal bladder functioning in as high as 96.7% of the affected women. Furthermore, use of this postoperative treatment strategy resulted in successful SUI outcomes in 95.1% of the patients.

Although slight variations in technique are described in the literature, tape mobilization typically involves a minor operation to reopen the incision, locate the tape and gently loosen the tape’s tension with a surgical instrument such as a clamp. This procedure, as opposed to other techniques designed to reposition the tape (i.e., Hegar rotation), entails a *controlled approach* to loosening the tension while under direct observation. Price et al.¹ identified the benefits of tape mobilization immediately after TVT placement as resolution of voiding problems, avoidance of long-term catheterization, and improved quality of life for patients.

While the term “tension-free” is used to describe this SUI treatment technique, it is a misnomer since a certain degree of tension/compression is needed to achieve a successful outcome following tape insertion. Due to the inherent risk of developing an obstruction of bladder functioning following TVT placement, appropriate guidelines for effective and timely management strategies are needed. Although differing views exist in the literature on the role of the position of the TVT relative to the LSM complex of the urethra in surgical outcomes,^{18–20} tapes

located <3 mm from the LSM have been found to increase the risk of obstructive complications.^{4,12} Postoperative voiding dysfunction is often the result of excessive tape tension.

If tapes are too tightly placed, mobilization should be done shortly after TVT insertion before tissue in growth and scar formation (typically within 2 weeks postoperatively¹), thus minimizing the need for sling incision and maximizing long-term effects of the original TVT procedure. As time elapses following tape insertion, the only viable option for dealing with most types of complications becomes tape incision. Postoperative complications requiring tape incision have the potential to result in recurrent SUIs.^{6,8,21}

Pelvic floor ultrasound aids in early identification of patients who will most likely benefit from this short and safe procedure. In cases of asymmetrically placed tapes, pelvic floor ultrasound helps to identify the side of the tape to be mobilized. In contrast to patients with a tape-LSM distance of ≥ 3 mm whose voiding problems often spontaneously improve after wound pain and edema subside, muscle spasms are relieved or the hematoma is resorbed; patients with a tape-LSM distance of <3 mm (a sonographic marker of too tightly placed tapes) seem to benefit from early tape mobilization without compromising the outcome of the initial procedure.^{4,12,15}

One noteworthy physiological characteristic observed in 29.5% of the study participants was a hypomobile urethra.¹⁷ Although urethral mobility is routinely measured for the entire population of women who undergo TVT placement procedures at both centers, the rate was not calculated for this study. Nevertheless, the difference between published rates of urethral hypomobility in all women having TVT procedures (10%) and this relatively high hypomobility rate found in our study population provides additional support to the claim that achieving the desirable tension level in cases of urethral hypomobility can be complex.²²

With regard to our repeated attempts at tape mobilization, the effect of the patients’ physiological factors (i.e., urethral mobility) on the assertiveness in technique of the operating physician when loosening the tape ought to be considered. When the tape is too conservatively loosened, it might only be stretched (not actually mobilized) and, in most cases, simply returns to its original position. Conversely, overly aggressive tape adjustments can potentially result in recurrent stress urinary incontinence. Despite the variation in assertiveness levels of the practitioners, our novel ultrasound-based approach to early tape mobilization involves a more controlled method to loosening the tape’s tension than other “blind” methods (i.e., Hegar rotation, downwards threads).

While the lack of a comparison group limits the generalizability of this study’s findings, the primary intent of the study was descriptive in nature. These favorable results and the practicality of broadly adopting ultrasound technology in early detection of postoperative complications justify an investment in further investigations. Subsequent assessments to estimate the impact of delayed detection and response on short- and long-term medical outcomes would be useful.

To our knowledge, the approach of using both ultrasonography and tape mobilization is not ordinarily practiced. This practical model links existing strategies and technology for a more proactive and timely response to postoperative complication management.

REFERENCES

1. Price N, Slack A, Khong SY, et al. The benefit of early mobilisation of tension-free vaginal tape in the treatment of post-operative voiding dysfunction. *Int Urogynecol J* 2009;20:855–858.

2. Chang WC, Sheu BC, Huang SC, et al. Postoperative transvaginal tape mobilization in preventing voiding difficulty after tension-free vaginal tape procedures. *Int Urogynecol J* 2010;21:229–233.
3. Klutke C, Siegel S, Carlin B, et al. Urinary retention after tension-free vaginal tape procedure: Incidence and treatment. *Urology* 2001;58:697–701.
4. Kociszewski J, Rautenberg O, Kuszka A, et al. Can we place tension-free vaginal tape where it should be? The one-third rule. *Ultrasound Obstet Gynecol* 2012;39:210–214.
5. Segal J, Steele A, Vassallo B, et al. Various surgical approaches to treat voiding dysfunction following anti-incontinence surgery. *Int Urogynecol J* 2006;17:372–377.
6. Viereck V, Rautenberg O, Kociszewski J, et al. Midurethral sling incision: Indications and outcomes. *Int Urogynecol J* 2013;24:645–653.
7. Nguyen JN. Tape mobilization for urinary retention after tension-free vaginal tape procedures. *Urology* 2005;66:523–526.
8. Glavind K, Glavind E. Treatment of prolonged voiding dysfunction after tension-free vaginal tape procedure. *Acta Obstet Gynecol Scand* 2007;86:357–360.
9. Flock F, Kohorst F, Kreienberg R, et al. Ultrasound assessment of tension-free vaginal tape (TVT). *Ultraschall Med* 2011;32:S35–S40.
10. Reich A, Muche R, Wiesner K, et al. Intraobserver and interobserver reliability of introital ultrasound after tension-free vaginal tape (TVT) procedure. *Ultraschall Med* 2011;32:E80–5.
11. Yang JM, Yang SH, Huang WC, et al. Reliability of a new method for assessing urethral compression following midurethral tape procedures using four-dimensional ultrasound. *Ultrasound Obstet Gynecol* 2011;38:210–216.
12. Kociszewski J, Rautenberg O, Perucchini D, et al. Tape functionality: Sonographic tape characteristics and outcome after TVT incontinence surgery. *Neurourol Urodyn* 2008;27:485–490.
13. Haylen BT, de Ridder D, Freeman RM, et al. An International Urogynecological Association (IUGA)/International Continence Society (ICS) joint report on the terminology for female pelvic floor dysfunction. *Neurourol Urodyn* 2010;29:4–20.
14. Ulmsten U. An introduction to tension-free vaginal tape (TVT)—A new surgical procedure for treatment of female urinary incontinence. *Int Urogynecol J* 2001;12:S3–S4.
15. Kociszewski J, Rautenberg O, Kolben S, et al. Tape functionality: Position, change in shape, and outcome after TVT procedure—Mid-term results. *Int Urogynecol J* 2010;21:795–800.
16. Viereck V, Pauer HU, Hesse O, et al. Urethral hypermobility after anti-incontinence surgery—A prognostic indicator? *Int Urogynecol J* 2006;17:586–592.
17. Viereck V, Nebel M, Bader W, et al. Role of bladder neck mobility and urethral closure pressure in predicting outcome of tension-free vaginal tape (TVT) procedure. *Ultrasound Obstet Gynecol* 2006;28:214–220.
18. Chantarasorn V, Shek KL, Dietz HP. Sonographic appearance of transobturator slings: Implications for function and dysfunction. *Int Urogynecol J* 2011;22:493–498.
19. Dietz HP, Mouritsen L, Ellis G, et al. How important is TVT location? *Acta Obstet Gynecol Scand* 2004;83:904–908.
20. Yang JM, Yang SH, Huang WC, et al. Correlation of tape location and tension with surgical outcome after transobturator suburethral tape procedures. *Ultrasound Obstet Gynecol* 2012;39:458–465.
21. Karram MM, Segal JL, Vassallo BJ, et al. Complications and untoward effects of the tension-free vaginal tape procedure. *Obstet Gynecol* 2003;101:929–932.
22. Meschia M, Pifarotti P, Gattei U, et al. Tension-free vaginal tape: Analysis of risk factors for failures. *Int Urogynecol J* 2007;18:419–422.