

See discussions, stats, and author profiles for this publication at: <https://www.researchgate.net/publication/283492924>

Vaginal excision of the sub-urethral sling: Analysis of indications, safety and outcome

Article in Archives of Medical Science · November 2015

DOI: 10.5114/aoms.2014.42305

CITATIONS

6

READS

52

8 authors, including:



[Jacek Kociszewski](#)

Lutheran Hospital, Hagen, Germany

39 PUBLICATIONS 297 CITATIONS

[SEE PROFILE](#)



[Ewa Barcz](#)

Medical University of Warsaw

82 PUBLICATIONS 572 CITATIONS

[SEE PROFILE](#)

Vaginal excision of the sub-urethral sling: analysis of indications, safety and outcome

George Fabian¹, Jacek Kociszewski¹, Andrzej Kuszka¹, Margarethe Fabian¹, Susane Grothey¹, Aneta Zwierzchowska², Wojciech Majkusiak², Ewa Barcz²

¹Department of Gynecology and Obstetrics, Evangelisches Krankenhaus Hagen-Haspe, Hagen, Germany

²1st Department of Obstetrics and Gynecology, Medical University of Warsaw, Warsaw, Poland

Submitted: 16 July 2013

Accepted: 18 October 2013

Arch Med Sci 2015; 11, 5: 982–988

DOI: 10.5114/aoms.2014.42305

Copyright © 2015 Termedia & Banach

Corresponding author:

Prof. Ewa Barcz MD, PhD

1st Department of Obstetrics

and Gynecology

Medical University of Warsaw

pl. Starynkiewicza 1/3

02-015 Warsaw, Poland

Phone: +48 601 362 918

E-mail: ewa.barcz@interia.pl

Abstract

Introduction: Sling techniques are the method of choice in stress urinary incontinence management, despite the high rates of complications leading sometimes to the necessity of re-operation, and the tape transection and resection are of the greatest importance. The study was aimed at analyzing the indications, technique and effects of transvaginal tape excision.

Material and methods: A retrospective study including 100 patients who underwent surgical removal of the sub-urethral sling in Evangelisches Krankenhaus Hagen-Haspe was conducted. The analyzed measures were: sling type, onset of symptoms, rates of particular complications, safety and outcome of the operative procedure.

Results: Most complications occurred in the first 2 years after surgery. The most common indications for re-operation were: overactive bladder (OAB) (64%), persistent stress urinary incontinence (SUI) (59%), pain (40%), urinary retention (40%), and erosion (29%). Some of the complications co-existed (i.e. vaginal erosion with postoperative pain, infections with urinary retention). During the procedure 1 bladder was injured and 1 patient had a hematoma. In women with OAB, 24-hour frequency decreased from 13.3 to 8.5 ($p < 0.001$), the mean voiding volume increased from 131.7 to 216.4 ml ($p < 0.001$), and nocturia increased from 3.28 to 1.19 ($p < 0.001$). Intensity of urgency decreased from 8.78 to 0.92 in the 10-point visual score ($p < 0.001$). Pain and urinary retention resolved in 39 out of 40 patients ($p < 0.0001$). The rate of SUI increased from 59% to 83% ($p < 0.001$).

Conclusions: Sling removal is safe and associated with a minimal rate of complications. Removing the tape causes resolution of most of the complications, but SUI recurs or worsens.

Key words: sling, complications, stress urinary incontinence treatment.

Introduction

Stress urinary incontinence (SUI) is the unintentional leakage of urine on exertion. It is estimated that the problem affects about one third of the female population worldwide [1].

Nowadays they constitute the gold standard, despite the fact that they are not free from adverse effects. The most severe intra-operative complication is bladder or urethra perforation. The most common complications of sling procedures are: overactive bladder (OAB), voiding difficulties, pain, tape erosion and treatment failure.

Voiding dysfunctions occur in 6–7% of the operated women [2, 3] and in most analyses it is more often for the retropubic tapes [4].

Overactive bladder is a complication that often causes dissatisfaction with SUI treatment. It is observed in 10–30% of patients [5]. It is agreed that OAB occurs more often following the insertion of the retropubic sling than the transobturator sling [6].

Postoperative pain affects up to 10% of patients and is more frequent in case of the transobturator approach. The lowest rates of this complication, however, are observed after insertion of mini slings [7, 8].

Another adverse effect that may occur following the sling procedure is its vaginal erosion. It complicates about 2–3% of cases [9, 10] and manifests clinically as vaginal discharge, dyspareunia and bleeding.

The most important aspect, robustly evaluated in relation to sling procedures, is their effectiveness. Depending on the author and duration of observation, it varies from 70% to 90% [11, 12]. It is now becoming agreed that an unsatisfactory result of the procedure is a complication that should be considered as a potential indication for re-intervention.

For some of the adverse effects of anti-incontinence surgery, re-operation turns out to be the treatment of choice. The extent of the surgery varies depending on the indications and the operator's experience. It consists of cutting the sling in the suburethral area and/or removing it through the vagina.

Taking into consideration the doubts concerning management options for complications of anti-incontinence surgery, as well as the treatment effects and ambiguous reports about the safety of re-interventions, the present study was aimed at analyzing the indications, surgical technique and effects of transvaginal removal of the sling as a method for complications of the sling procedures.

Material and methods

The retrospective analysis of data of 100 patients who underwent surgical removal of the sub-urethral sling in Evangelisches Krankenhaus Hagen-Haspe, a tertiary urogynecological center, in the years 2010–2012, was made. The patients were collected consecutively as they were admitted to the clinic from January 2010 to December 2012. None of them was removed from the analysis. The analyzed measures were: date and type of the inserted sling (all were polypropylene slings), onset of adverse symptoms, safety and outcome of procedure. In all cases, symptoms reported by patients were verified by full urogynecological examinations before and after sling removal.

In all cases pelvic floor ultrasound examination with the probe (a 3.6–8.3 MHz vaginal transducer

with a beam angle of 160°) placed in the vaginal introitus at the level of the external urethral orifice was performed.

The tape localization with respect to bladder neck and urethra lumen was performed and analyzed (no published results).

Each patient was informed about the risk of the procedure as well as the high probability of worsening of incontinence and the necessity of re-operation.

Patients were operated on in general anesthesia in the lithotomy position. Duration of the procedures varied from 20 to 45 min. First, urethrocytoscopy was performed in order to exclude bladder or urethra perforation. To facilitate the localization of the tape, a no. 6 Hegar dilator was inserted into the urethra. The dilator was then lowered in order to put the sling into tension. Subsequently, the vagina was incised to reach the central part of the tape, then the tape was incised. The edge of the tape was grasped and dissected sharply and bluntly until the pubic arch or obturator foramen was reached. The procedure was repeated for the other side as described previously [13]. Following the procedure, the Foley catheter was kept up to 7 days. Antibiotics and estriol vaginally were administered routinely.

Statistical analysis

The changes in means of variables before and after the surgery were evaluated using the *t*-test for paired data. Each time, normality was verified with the Shapiro-Wilk test. In case of lack of normality of compared distributions, the Wilcoxon matched-pairs signed-ranks test was used instead of the *t*-test.

Similarly, when comparing means in non-paired data, the *t*-test was used. When two samples had unequal variances Welch's *t*-test was applied instead. The robust Wilcoxon-Mann-Whitney test was additionally used when the distributions lacked normality.

The ANOVA model was applied for comparison of variables' means if several groups were analyzed. Homoscedasticity was controlled with Bartlett's test for equal variances. In case of unequal variances the Kruskal-Wallis rank test was used instead of the ANOVA model.

The density functions were estimated using a non-parametric kernel approach with Epanechnikov kernel function.

The statistical analysis was performed using STATA 11.1 SE (Stata Corp LP, Texas, USA).

Results

Data of 100 patients were analyzed. All women underwent removal of a sub-urethral sling as management of complications. Three of them had

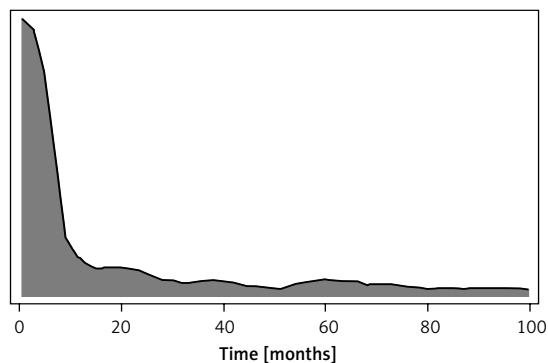


Figure 1. Estimated distribution of time from insertion of the sling to the occurrence of the complication

undergone two sling procedures and had two different slings.

Due to the nature of the data, one cannot draw conclusions about the associations of certain complications with certain types of slings. This is due to the fact that women qualified for sling removal had undergone a sling procedure in other units and the rates of particular sling procedures in those centers are unknown.

The mean age of the patients at the time of sling removal was 61.5 (38–83) years. The mean time that passed from the date of sling insertion to the removal was slightly above 3 years. A complication occurred just over one year following the last sling procedure on average (mean: 13.5 months, SD = 24.4). In 48 patients, an adverse effect appeared directly post-surgery that might be connected with impaired surgery technique, in 71 women within 6 months and in 89 women within 2 years after the procedure. When 2 years passed, the probability of a complication remained relatively low (Figure 1).

Indications for sling removal

The indications for sling removal are shown in Table I. An analysis of the correlations between complications constituting indications for sling removal with particular sling procedures was conducted.

Table I. Indications for sling removal

Complication	Number of patients	Percent of the research group
OAB	64	64
SUI	59	59
Pain, including: dyspareunia, spontaneous pain, pain on walking, dysuria	40	40
Urinary retention:	40	40
Partial retention with overflow incontinence	16	16
Tape erosion	25	25

Table II presents the number of complications and their relative frequency (that is in relation to the number of patients with the given sling).

The OAB was the most common complication leading to the necessity of sling removal – it was diagnosed in 64 patients. Relative frequencies of this complaint were similar in all types of slings, that is approximately 60%. The diagnosis was based on incidence of symptoms according to ICS guidance from 2002 (nocturia, pollakiuria, urge sensation) on the basis of anamnesis and bladder diary, without urodynamic test. All of the patients had a history of ineffective treatment with anticholinergics from 1 to 3 months outside our center.

98.7% of women diagnosed with overactive bladder suffered from nocturia (mean number of night urinations was 3.25) and pollakiuria (mean number of urinations was 13.2 ± 2.4 diurnally, and mean urination volume was 132 ± 37 ml). Wet OAB form affected 25% of the whole group. Intensity of urgency was 8.78 in the 10-point visual complaint score.

The second most common complication was persistent SUI, which was observed in 59% of patients. No differences in the rates of this side effect were observed in different sling types. Persistent SUI was an indication for tape excision as according to our experience the results of new tape insertion after tape removal instead of implantation of a second one in the presence of the first one are significantly better (no published data). The SUI was diagnosed on the basis of cough test as well as 1-hour pad test (mean urine loss was 100.9 ± 65.4 g).

Forty percent of patients suffered from pain: dyspareunia (29%), spontaneous (27%), on walking (3%) and dysuria (2%). There were no statistically significant correlations between types of slings and pain.

Partial urinary retention occurred in 40% of the patients. In 16%, overflow incontinence accompanying retention was observed. The mean residual volume was 206 ± 130 ml. The residual volume was greater in women with overflow incontinence: 286 ± 151.

Table II. Number and relative frequency of particular complications in relation to the sling types

Sling type	Subgroup quantity n	OAB n (%)	SUI n (%)	Pain n (%)	Urinary retention n (%)	Recurrent bladder infections n (%)	Tape erosion n (%)
All slings	100	64 (64)	59 (59)	40 (40)	40 (40)	25 (25)	25 (25)
Retropubic slings:	52	34 (65)	26 (50)	20 (38)	25 (48)	18 (35)	8 (15)
TVT	44	29 (66)	22 (50)	16 (36)	22 (50)	18 (41)	5 (11)
TVT-Exact	4	2 (50)	2 (50)	2 (50)	2 (50)	0 (0)	2 (50)
TVT-Seraxis	2	2 (100)	1 (50)	1 (50)	1 (50)	0 (0)	0 (0)
IVS	2	1 (50)	1 (50)	1 (50)	0 (0)	0 (0)	1 (50)
Transobturator slings:	45	28 (62)	32 (71)	19 (42)	13 (29)	7 (16)	17 (38)
TVT-O	18	11 (61)	11 (61)	8 (44)	7 (39)	2 (11)	6 (33)
TOT	15	7 (47)	12 (80)	5 (33)	4 (27)	2 (13)	8 (53)
TOT-Obtape	6	4 (67)	5 (83)	4 (67)	1 (17)	1 (17)	3 (50)
TOT-Monarc	4	4 (100)	2 (50)	1 (25)	1 (25)	1 (25)	0 (0)
TOT-Aris	1	1 (100)	1 (100)	0 (0)	0 (0)	0 (0)	0 (0)
TVT-O Abrevo	1	1 (100)	1 (100)	1 (100)	0 (0)	1 (100)	0 (0)
Two slings	3	2 (66)	1 (33)	1 (33)	2 (67)	0 (0)	0 (0)

Women with retropubic slings, presenting with urinary retention, had a greater mean residual volume than those with transobturator slings (206 ml vs. 157 ml, $p = 0.61$). The mean in women with two slings was significantly higher than in the other two groups ($p = 0.0004$ in comparison with retropubic tapes and < 0.0001 in comparison with transobturator tapes) – Figure 2.

Mesh erosion occurred in 25% of patients. This complication was never the only indication for sling removal. The relative frequency of erosion was more than twice as high in patients with transobturator tapes than those with retropubic tapes (38% vs. 15%, $p = 0.034$). All of the patients with tape erosion were treated pre-operatively with local estrogens for at least 3 months.

In 25% of women, recurrent bladder infections were observed. Some of the patients suffered from more than one postoperative complication. Sling erosion and pain were the most commonly co-existing complications. Pain occurred in 40% of the whole research group and in 80% of the subgroup with erosion.

Recurrent bladder infections and urinary retention constituted another pair of complications. Infections occurred in 25% of the study group and in 45% of patients with retention.

Analysis of the procedure

All patients underwent sling removal. In 1 (1%) patient, the urinary bladder was injured. One (1%) had a postoperative hematoma. The mean blood

loss was 13.7 ± 14.5 ml. One patient lost 150 ml and this was related to bladder perforation. No other complications occurred.

Effects of the operation

Among 64 women with OAB (according to bladder diary), sling removal caused a decrease in the 24-hour frequency (from 13.3 to 8.5; $p < 0.001$) and an increase in the mean urination volume (131.7 ml to 216.4 ml; $p < 0.001$). Following the procedure, the average number of voids at night decreased from 3.28 to 1.19 ($p < 0.001$). The intensity of urgency decreased from 8.78 to 0.92 in the 10-point visual complaint score ($p < 0.001$) (Figure 3).

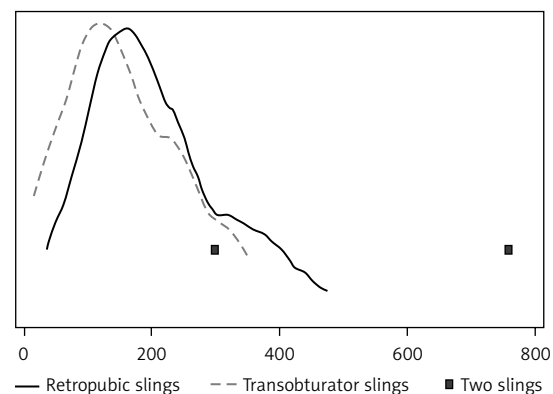


Figure 2. Estimated distribution of residual volumes for the two sling types

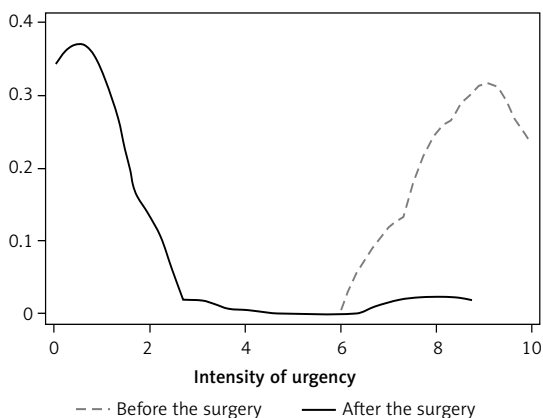


Figure 3. Estimated distribution of urgency in 10-point visual score before and after sling removal

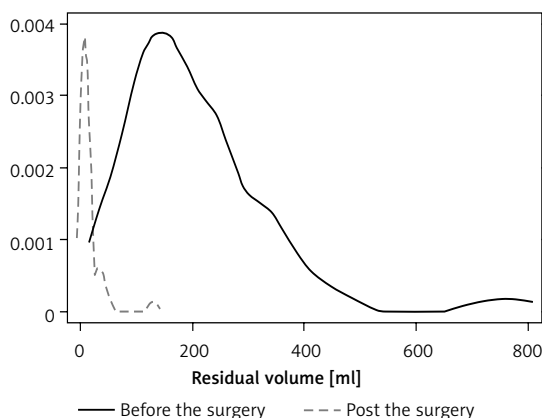


Figure 4. Estimated distributions of residual volume before and post-surgery

Removal of the sling led to a significant increase in the rate of SUI in the research group – from 59% to 83% ($p < 0.001$). The mean result of the pad test increased both in patients who had and those who had not had SUI before the surgery by 35.5%. In 2 patients, sling removal resulted in resolution of SUI, whereas 26 patients became incontinent after the operation. Fifty-seven women suffered from SUI both before and after surgery. In 15 women no symptoms of SUI were observed either before or after sling removal.

Following the sling removal, pain resolved in 39 out of 40 patients who suffered from this symptom before the surgery. Only in 1 patient did spontaneous pain remain. In 1 patient, dyspareunia occurred after the surgery, although she had not suffered from it before.

In all 40 patients who had urinary retention before the surgery, the operation caused a decrease in the residual volume – by 191.5 ml on average. The mean residual volume decreased from 206.4 ml to 14.9 ml ($p < 0.001$). The maximal residual volume decreased from 760 to 130 ml. In all patients but one the residual volume post-surgery was less than or equal to 50 ml (Figure 4).

Surgical removal of the sling resulted in a significant decrease in the rates of patients using the Valsalva maneuver during urination (from 76% to 40%, $p < 0.0001$), and having to micturate in a non-physiological position (from 19% to 1%, $p < 0.0001$).

Discussion

Postoperative complications of anti-incontinence surgery are quite common, but those necessitating surgical re-interventions occur only in a few percent of cases. Nevertheless, their severity was the purpose of an FDA warning from 2008 and following years (FDA Public Health Notification: Serious Complications Associated with Transvaginal Placement of Surgical Mesh in Repair of Pelvic Organ Prolapse and Stress Urinary Incontinence).

In the current literature, reports about indications for surgical intervention, the technique and effects are often inconsistent.

The present study was conducted on patients qualified for sub-urethral sling removal for various indications.

The OAB was the most common indication for sling removal. All the patients underwent a failed attempt at anticholinergic treatment before surgery. The visual complaint score decreased from 8.78 to 1.19 as urgency was concerned, whereas pollakiuria and nocturia subsided in about 90%. The results achieved by Viereck *et al.*, by cutting the sling, were significantly worse – the rate of symptom resolution reached only 60% [14].

In the present study, 40% of women were qualified for the surgery due to urinary retention. The problem occurred significantly more often in patients with retropubic tapes. This result confirms the findings of other authors depending on different surgical techniques [7].

When urinary retention occurs, the standard management consists of prolonged catheterization of the bladder mainly to resolve edema. However, delayed removal of the catheter often does not help and surgery is necessary [15]. Another treatment option in urinary retention is surgical re-intervention. Choosing the best approach is a subject for a wide discussion. Questions arise about the technique and portion of the sling where it should be cut – centrally or laterally. Some surgeons cut it in two places, at the 9 and 3 o'clock position, so that a part of the sling posterior to the urethra stays intact [16]. Viereck *et al.* also cut the tapes in cases of urinary retention complicating sling procedures [14]. This procedure brought virtually immediate effects in 97% of patients with voiding dysfunction and urinary retention following sling insertion. In another multicentre retrospective study, with surgical intervention consisting of cutting the sling, removing the sling or loosening it, voiding dysfunctions resolved in 80% of cases [17].

In an Australian analysis of 63 cases re-operated during an 11-year period, resolution of voiding dysfunction was achieved in 87%, and the authors detected no differences with regard to the technique – cutting the sling or excising it [18]. When retention is diagnosed immediately after surgery, early mobilization of the tape should be considered [19].

In the present study, urinary retention and voiding dysfunctions subsided in 99% of women. The mean residual volume decreased from 206.4 ml to 14.9 ml. Improvement was observed directly after the surgery.

Postoperative pain following sling insertion can be managed with many conservative methods. As the first-line treatment, local antibiotics and estrogens or oral non-steroid anti-inflammatory drugs/steroids are used [20]. In chronic pain, surgical re-intervention is the method of choice.

In the current study, out of the 100 patients, 40 had their slings removed because of postoperative pain. The procedure caused resolution of pain in 39 (99%) of women. The therapeutic effect in relation to pain is better in the present study than when the sling was cut. In the study conducted by Viereck *et al.*, pain subsided in only 82% of patients [14].

As mentioned above, vaginal erosion of the sling occurs in about 4% of patients. The first line treatment is non-surgical – local estrogens and antibiotics – and only in case of failure should surgical treatment be considered. This may consist of removing the eroded portion of the tape or removing the whole tape.

According to the literature, the symptoms that were the direct indications for surgery resolved [21, 22]. Similarly, in the current study, the complaints related to erosion subsided after the operation.

Incomplete effectiveness or failure of the sling procedure, as well as managing the problem, is another important issues to solve.

There are researchers reporting a possible treatment option – inserting another sub-urethral tape. In a study with 80 patients treated this way, the cure rate was 61%, while improvement was achieved in 74 [23]. In an analysis performed by Meyer, the repeat sling procedure was evaluated in 112 patients. The subjective cure rate was 60.7%, whereas the improvement rate reached an additional 16% [24].

Lee *et al.* reported that the repeat sling procedure is associated with a cure rate of 75% [25]. All authors emphasized the evident difference between the rate of ineffectiveness diagnosed by the doctors (30%) and that reported subjectively by the patients (42%) [26].

Despite the encouraging results of the repeat tape, one may be alarmed by other reports, which

indicate that the procedure is associated with significant rates of *de novo* OAB [27]. In an analysis of the effects of SUI treatment of patients with the transobturator tape, the results of inserting an additional retropubic tape were satisfactory (about 80% of patients with improvement), but the rate of OAB was alarming since it reached 21% [28].

Another technique used to treat an unsatisfactory effect of the sling procedure is plication of the tape with sutures placed at the level of the central portion of the urethra, with improvement in 85% of women [29].

The question that is of greater importance when we opt for a surgical re-intervention is which technique we should choose. As described above, cutting the tape is very effective in most of the patients suffering from urinary retention, detrusor instability or postoperative pain, but in most of the cases, incontinence recurs (50–90%, depending on the author).

When the tape is cut, along with recurring SUI, inserting a new tape resolves the SUI problem, but as mentioned before it often causes OAB *de novo* and a very inconvenient clinical situation, where removing the first tape is technically extremely difficult. In this case, when SUI recurs, it is of course necessary to insert another tape without removing the first one. The procedure, as mentioned before, is effective in 60–70% of cases, but some patients will still remain incontinent and in about 20% urgency will occur, causing dissatisfaction with the treatment.

Taking these issues into consideration, it seems that removing the tape is a better method to treat complications after sling insertion. Since it became clear that the majority of failures of SUI treatment are caused by inappropriate localization of the tape, it seems that removing the sling and inserting another one in the correct position is the best solution with regard to all analyzed complications (no published data). When performing a repeat sling procedure, it is also beneficial to consider the results of the ultrasound examination of the pelvic floor [30–32].

In conclusion, it should be stated that the most common indications for sling removal were: overactive bladder, urinary retention, postoperative pain and ineffectiveness of the primary treatment. The technique used to remove the tape is safe and associated with a minimal rate of complications. The effects of the surgery are better as compared to the results of cutting the tape in all analyzed aspects, whereas stress incontinence recurs or worsens. Finally, it should be stressed that the complete removal of the vaginal portion of the tape creates the optimal conditions to insert a new tape as the next step of management in a complicated patient.

Conflict of interest

The authors declare no conflict of interest.

References

- Bradley CS, Nygaard IE, Mengeling MA, et al. Urinary incontinence, depression and posttraumatic stress disorder in women veterans. *Am J Obstet Gynecol* 2012; 206: 502.e1-8.
- Kuuva N, Nilson CG. A nationwide analysis of complications associated with the tension free vaginal tape (TVT) procedure. *Acta Obstet Gynecol Scand* 2002; 81: 72-7.
- Reich A, Kohorst F, Kreienberg R, Flock F. Voiding dysfunction after the tension-free vaginal tape procedure. *Gynecol Obstet Invest* 2011; 72: 79-84.
- Yang X, Jiang M, Chen X, et al. TVT-O vs. TVT for the treatment of SUI: a non-inferiority study. *Int Urogynecol J* 2012; 23: 99-104.
- Serati M, Ghezzi F, Cattoni E, et al. Tension-free vaginal tape for the treatment of urodynamic stress incontinence: efficacy and adverse effects at 10-year follow-up. *Eur Urol* 2012; 61: 939-46.
- Botros SM, Miller JJR, Goldberg RP, et al. Detrusor overactivity and urge urinary incontinence following trans obturator versus midurethral slings. *Neurourol Urodyn* 2007; 26: 42-5.
- Latthe PM, Foon R, Toozs-Hobson P. Transobturator and retropubic tape procedures in stress urinary incontinence: a systematic review and meta-analysis of effectiveness and complications. *BJOG* 2007; 114: 522-31.
- Lee KS, Lee YS, Seo JT. A prospective multicenter randomized comparative study between the U- and H-type methods of the TVT SECUR procedure for the treatment of female stress urinary incontinence: 1-year follow-up. *Eur Urol* 2010; 57: 973-9.
- Latthe PM, Foon R, Toozs-Hobson P. Transobturator and retropubic tape procedures in stress urinary incontinence: a systematic review and meta-analysis of effectiveness and complications. *BJOG* 2007; 114: 522-31.
- Rechberger T, Futyma K, Jankiewicz K, Adamiak A, Skorupski P. The clinical effectiveness of retropubic (IVS-02) and transobturator (IVS-04) midurethral slings: randomized trial. *Eur Urol* 2009; 56: 24-30.
- Reich A, Kohorst F, Kreienberg R, Flock F. Long-term results of the tension-free vaginal tape procedure in an unselected group: a 7-year follow-up study. *Urology* 2011; 78: 774-7.
- Angioli R, Plotti F, Muzii L, Montera R, Panici PB, Zullo MA. Tension-free vaginal tape versus transobturator sub-urethral tape: five-year follow-up results of a prospective, randomised trial. *Eur Urol* 2010; 58: 671-7.
- Wiedemann A, Kociszewski J. The "Hegar test" facilitates detection of a dystopic sub-urethral band. *Aktuelle Urol* 2012; 43: 144.
- Viereck V, Rautenberg O, Kociszewski J, Grothey S, Veltner JE, Eberhard J. Midurethral sling incision: indications and outcomes. *Int Urogynecol J* 2013; 24: 645-53.
- Glavind K, Glavind E. Treatment of prolonged voiding dysfunction after tension-free vaginal tape procedure. *Acta Obstet Gynecol Scand* 2007; 86: 357-60.
- Kasturi S, Hale DS. "J" cut of sling for postoperative voiding dysfunction following synthetic midurethral slings. *Int Urogynecol J* 2011; 22: 933-6.
- Molden S, Bracken J, Nguyen A, et al. A retrospective multicenter study on outcomes after midurethral polypropylene sling revision for voiding dysfunction. *Female Pelvic Med Reconstr Surg* 2010; 16: 340-4.
- Agnew G, Dwyer PL, Rosamilia A, Edwards G, Lee JK. Functional outcomes for surgical revision of synthetic slings performed for voiding dysfunction: a retrospective study. *Eur J Obstet Gynecol Reprod Biol* 2012; 163: 113-6.
- Rautenberg O, Kociszewski J, Welter J, Kuszka A, Eberhard J, Viereck V. Ultrasound and early tape mobilization – a practical solution for treating postoperative voiding dysfunction. *Neurourol Urodyn* 2013 Jul 2. doi: 10.1002/nau.22459. [Epub ahead of print]
- Duckett J, Baranowski A. Pain after sub-urethral sling insertion for urinary stress incontinence. *Int Urogynecol J* 2013; 24: 195-201.
- Volkmer BG, Nessler T, Rinnab L, Schradin T, Hautmann RE, Gottfried HW. Surgical intervention for complications of tension-free vaginal tape procedure. *J Urol* 2003; 169: 570-4.
- Huang KH, Kung FT, Liang HM, Chang SY. Management of polypropylene mesh erosion after intravaginal midurethral sling operation for female stress urinary incontinence. *Int Urogynecol J Pelvic Floor Dysfunct* 2005; 16: 437-40.
- Verbrugghe A, De Ridder D, Van der Aa F. A repeat mid-urethral sling as valuable treatment for persistent or recurrent stress urinary incontinence. *Int Urogynecol J* 2012; 24: 999-1004.
- Meyer F, Hermieu JF, Boyd A, et al. Repeat mid-urethral sling for recurrent female stress urinary incontinence. *Int Urogynecol J* 2013; 24: 817-22.
- Lee KS, Doo CK, Han DH, Jung BJ, Han JY, Choo MS. Outcomes following repeat mid urethral synthetic sling after failure of the initial sling procedure: rediscovery of the tension-free vaginal tape procedure. *J Urol* 2007; 178: 1370-4.
- Van Baelen AA, Delaere KP. Repeat transobturator tape after failed mid-urethral sling procedure: follow-up with questionnaire-based assessment. *Urol Int* 2009; 83: 399-403.
- Stav K, Dwyer PL, Rosamilia A, et al. Repeat synthetic mid urethral sling procedure for women with recurrent stress urinary incontinence. *J Urol* 2010; 183: 241-6.
- Sabadell J, Poza JL, Esgueva A, Morales JC, Sánchez-Iglesias JL, Xercavins J. Usefulness of retropubic tape for recurrent stress incontinence after transobturator tape failure. *Int Urogynecol J* 2011; 22: 1543-7.
- Patterson D, Rajan S, Kohli N. Sling plication for recurrent stress urinary incontinence. *Female Pelvic Med Reconstr Surg* 2010; 16: 307-9.
- Kociszewski J, Rautenberg O, Kolben S, Eberhard J, Hilgers R, Viereck V. Tape functionality: position, change in shape, and outcome after TVT procedure: mid-term results. *Int Urogynecol J* 2010; 21: 795-800.
- Kociszewski J, Rautenberg O, Kuszka A, Eberhard J, Hilgers R, Viereck V. Can we place tension-free vaginal tape where it should be? The one-third rule. *Ultrasound Obstet Gynecol* 2012; 39: 210-4.
- Kociszewski J, Rautenberg O, Perucchini D, et al. Tape functionality: sonographic tape characteristics and outcome after TVT incontinence surgery. *Neurourol Urodyn* 2008; 27: 485-90.